



Anatomic identification of nerve-sparing radical hysterectomy: A step-by-step procedure

Shingo Fujii*

National Hospital Organization: Kyoto Medical Center, Kyoto, Japan

Received 3 July 2008

Abstract

The radical hysterectomy is often associated with severe bladder dysfunction and colorectal motility disorders. These issues may arise as a result of damage incurred to the motor and sensory autonomic nerve supply, both of sympathetic and parasympathetic origin, that innervate the uterus, vagina, urinary bladder, and rectum. In this article, we demonstrate a fertility-sparing radical hysterectomy using illustrations and step-by-step instructions.

© 2008 Elsevier Inc. All rights reserved.

Keywords: Nerve-sparing radical hysterectomy; Radical hysterectomy; Bladder dysfunction; Colorectal motility disorders

Introduction

Several modifications have been made to the radical hysterectomy since Ernst Wertheim first introduced the surgical procedure in 1911 [1]. In western countries, the radical hysterectomy classified by Piver, Rutledge and Smith (class III) [2] is considered the standard approach to the radical hysterectomy. In eastern countries, however, particularly in Japan, the Okabayashi method [3] is the standard approach to the radical hysterectomy. Both methods similarly separate the anterior leaf of the vesicouterine ligament, but there is a different approach in regards to the separation of the posterior leaf of the vesicouterine ligament. The class III method divides the paravaginal tissues together with the posterior leaf of the vesicouterine ligament and the paracolpium (vaginal blood vessels). In contrast, the Okabayashi method separates and divides the posterior leaf of the vesicouterine ligament intentionally, and then the paracolpium is isolated and divided. The latter procedure enables the surgeon to separate the bladder with the ureter completely away from the lateral side of the cervix and vagina and allows for the easy resection of any

vaginal length deemed appropriate for the optimization of the radical hysterectomy. However, both types of radical hysterectomy have been often associated with severe bladder dysfunction and colorectal motility disorders.

The uterus, vagina, urinary bladder, and rectum are innervated by a motor and sensory autonomic nerve supply, both of sympathetic and parasympathetic origin. The sympathetic fibers come from T11-L2 and form the superior hypogastric plexus. The parasympathetic fibers come from S2, 3, and 4 at the pelvic wall as the pelvic splanchnic nerve. These fibers merge and form the inferior hypogastric plexus and branch to innervate the uterus and the urinary bladder. It has been reported that during a radical hysterectomy the hypogastric nerve is often sacrificed when the surgeon divides the uterosacral ligament and rectovaginal ligament; the pelvic splanchnic nerve is often sacrificed when the surgeon divides the deep uterine vein in the cardinal ligament; and the bladder branch of the pelvic nerves is often sacrificed when the surgeon ligates and divides the paracolpium [4].

However, the anatomy of the inferior hypogastric plexus encompassing the hypogastric nerve, the pelvic splanchnic nerve, and the bladder branch/the uterine branch from this plexus is complicated and is not easy to appreciate during surgery. In order to accomplish a nerve-sparing radical hysterectomy, it is absolutely necessary to reveal the inferior

* Fax: +81 75 643 8156.

E-mail address: sfu@kuhp.kyoto-u.ac.jp.

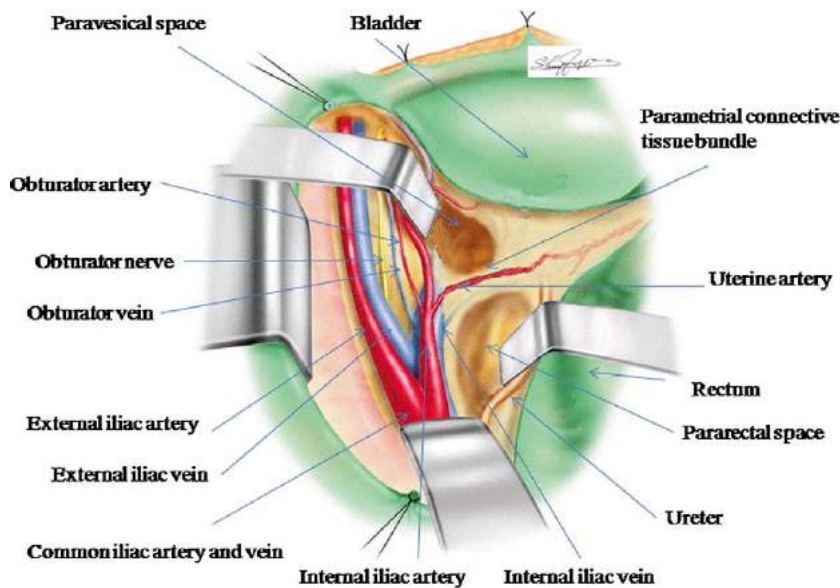


Fig. 1. Development of the pararectal space and paravesical space.

hypogastric plexus and to transect only the uterine branch from the inferior hypogastric plexus. In this way, we can preserve the hypogastric nerve, the pelvic splanchnic nerve, and the bladder branch from the inferior hypogastric plexus.

Here, we demonstrate the operative procedure using illustrations and step-by-step instructions. Our recent paper on the anatomy involved in a nerve-sparing radical hysterectomy [4], which included photos and illustrations on how to identify the inferior hypogastric plexus, as well as our report on the anatomy of the vesicouterine ligament (anterior/posterior) [5] can help in the understanding of the entire anatomy of the inferior hypogastric plexus.

Operative procedure

Only the operative steps of the left side of the patient, which are necessary to identify the anatomical structures of the pelvic nerves, are described.

Step 1: Isolation and separation of the deep uterine vein from the pelvic splanchnic nerve

After pelvic lymphadenectomy, we develop the pararectal space and the paravesical space and create the parametrial connective tissue bundle in which the uterine artery, the superficial uterine vein, and the deep uterine vein are

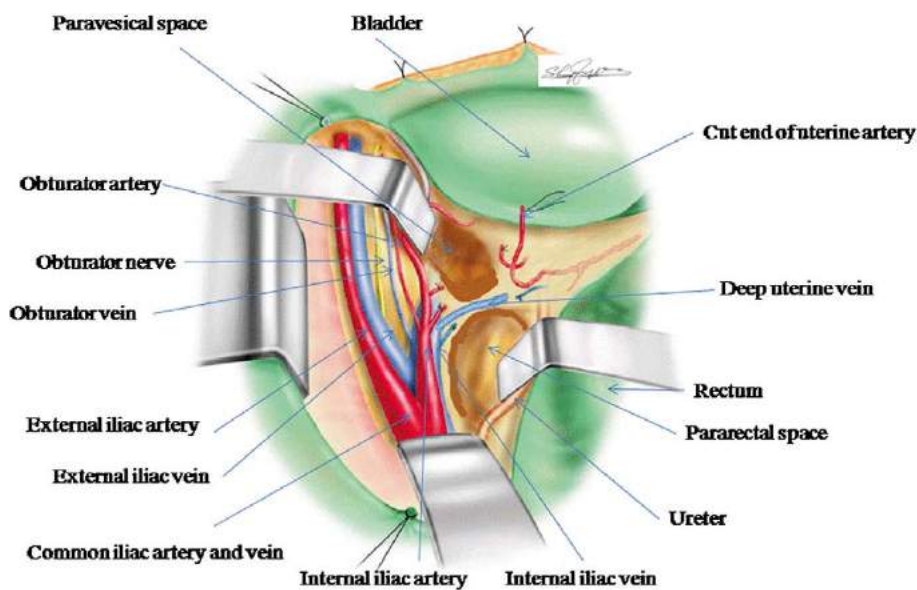


Fig. 2. Isolation of the deep uterine vein.

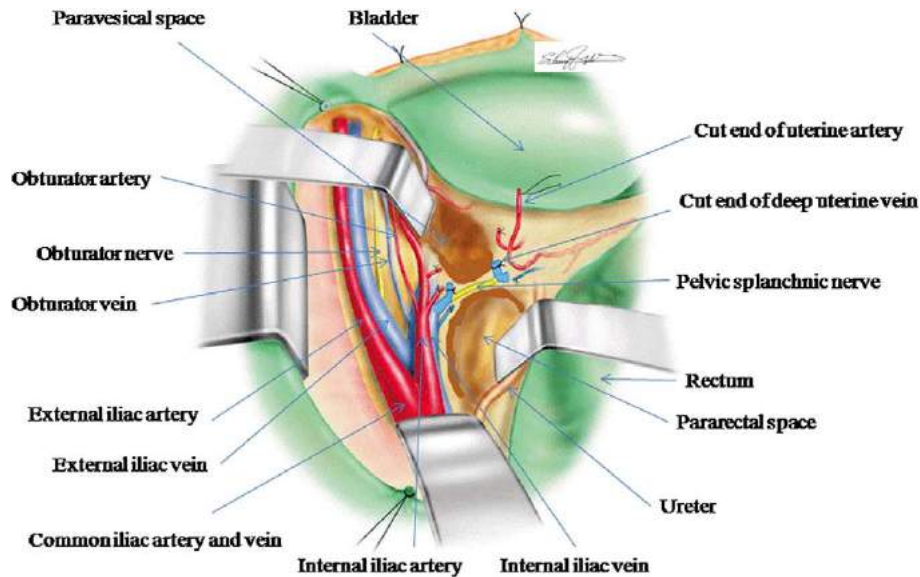


Fig. 3. Division of the deep uterine vein reveals the pelvic splanchnic nerve.

included (Fig. 1). The uterine artery and superficial uterine vein are respectively isolated, clamped, cut, and ligated. The subsequent removal of the connective tissue, fatty tissue, and lymph nodes in the deeper portion of the parametrial connective tissue reveals the deep uterine vein (Fig. 2). By the isolation and division of the deep uterine vein, we usually appreciate one of the branches of the pelvic splanchnic nerves (Fig. 3) which runs toward the inferior hypogastric plexus.

Step 2: Isolation and separation of the hypogastric nerve

On the rectal side of the pararectal space, a white bundle of the hypogastric nerve runs parallel to the rectum. The hypogastric nerve is isolated and a vessel tape is applied as a marker (Fig. 4).

Step 3: Separation of the connective tissue between the rectum and the vagina

The peritoneum of the pouch of Douglas and posterior peritoneal leaves of the broad ligament are transversely incised. The connective tissue on the vaginal wall is separated from the central wall of the rectum deep enough to permit extirpation of an ample vaginal cuff.

Step 4: Division of the uterosacral ligament

By the separation of the vaginal wall from the rectum and, thereafter, pushing the rectum up, the uterosacral ligament becomes visible between the lateral sidewall of the uterus and the rectum. The connective tissue of the uterosacral ligament is divided without including the hypogastric nerve.

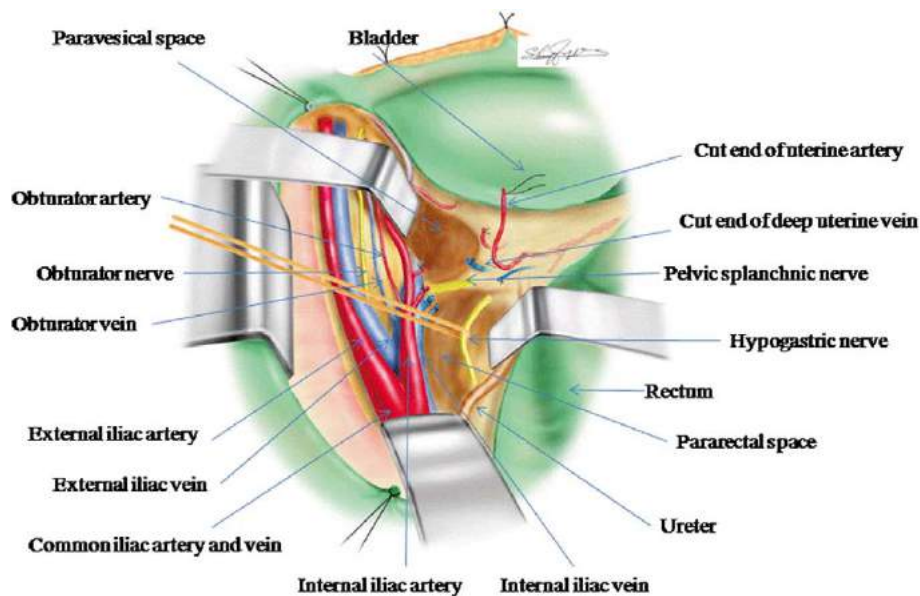


Fig. 4. Isolation and division of the hypogastric nerve.

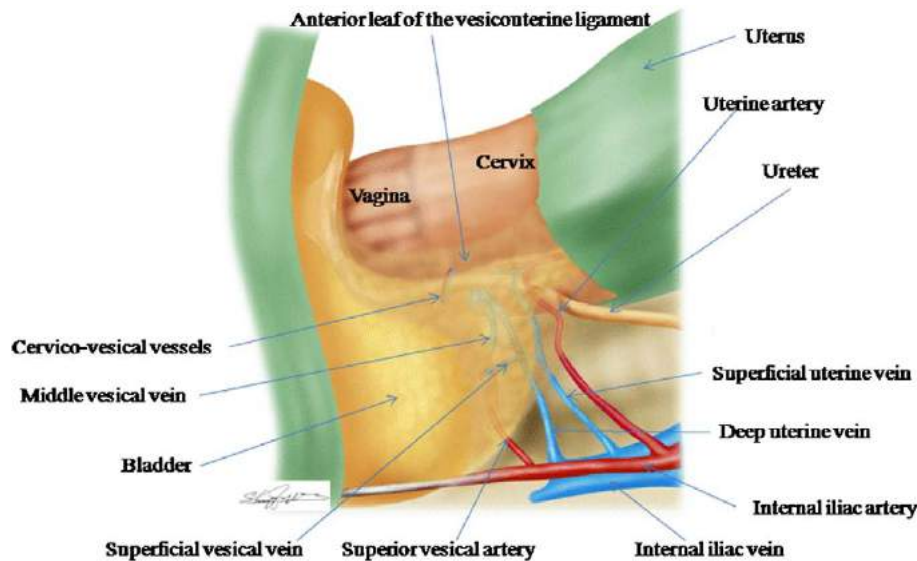


Fig. 5. The anterior leaf of the vesicouterine ligament.

Step 5: Separation of the cut end of the deep uterine vein from the pelvic splanchnic nerve

If we pick up the cut end of the deep uterine vein, we can appreciate that the deep uterine vein of the uterine side runs parallel to the pelvic splanchnic nerve in the rectal lateral wall. Usually, it is not difficult to separate the deep uterine vein from the connective tissue that includes the branch of the splanchnic nerve down to the level of the inferior hypogastric plexus.

Step 6: Separation of blood vessels in the anterior leaf of the vesicouterine ligament

The bladder is separated from the central wall of the cervix down to the cranial level of the trigone of the urinary bladder. Connective tissue on the side of the cervix is carefully separated (Fig. 5). Then, by meticulous separation of the connective tissues in the anterior leaf of the

vesicouterine ligament (Fig. 5) as reported previously, the ureter is completely freed of its attachment to the posterior leaf of the vesicouterine ligament (Fig. 6).

Step 7: Separation of blood vessels in the posterior leaf of the vesicouterine ligament

The connective tissue in the posterior leaf of the vesicouterine ligament is carefully separated (Fig. 7), and the middle vesical vein, which runs from the urinary bladder to the cervix draining into the deep uterine vein, is isolated, doubly clamped, divided, and ligated (Fig. 8). In addition, we can appreciate the inferior vesical vein that runs parallel to the cervix from the posterior portion of the urinary bladder, which also drains into the deep uterine vein. When the inferior vesical vein is isolated, the vein is doubly clamped, divided, and ligated (Fig. 9).

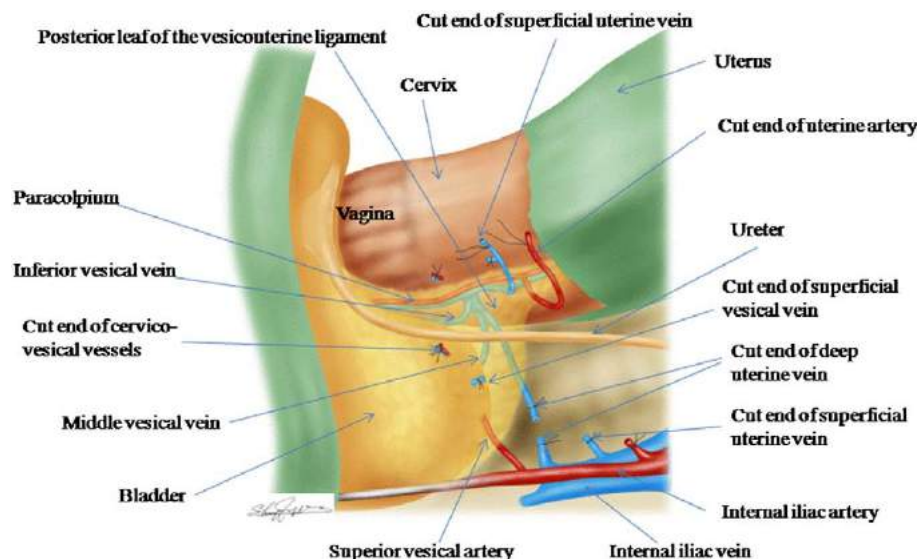


Fig. 6. The posterior leaf of the vesicouterine ligament.

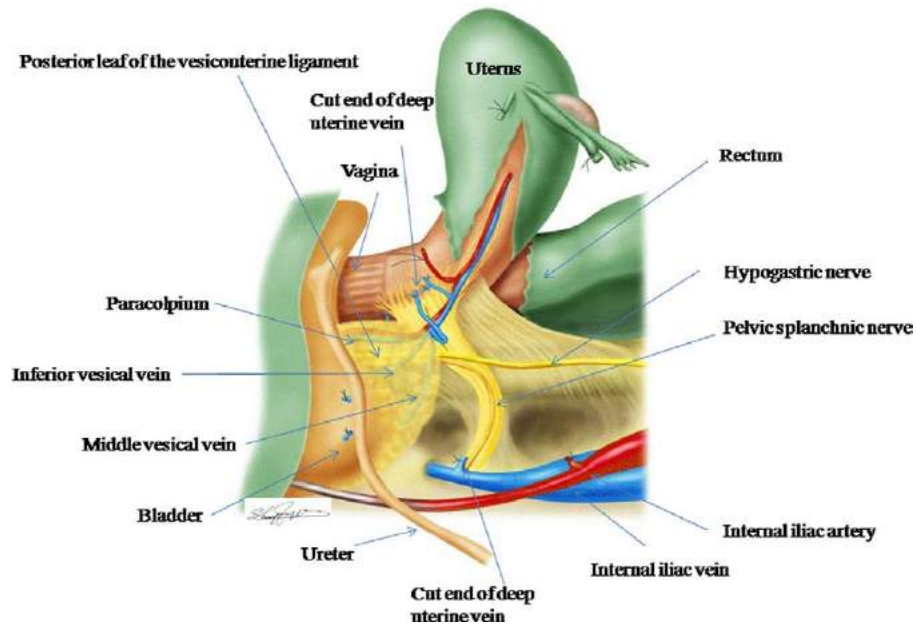


Fig. 7. Blood vessels in the posterior leaf of the vesicouterine ligament.

Step 8: Identification of the bladder branch from the inferior hypogastric plexus

After the removal of the fatty tissues residing between the dorsal portion of the urinary bladder and the rectal sidewall, tracing the splanchnic nerve toward the inferior hypogastric plexus, we can appreciate definite nerve bundles running from the plexus to the bladder beneath the inferior vesical vein (Fig. 9). The bladder branch from the inferior hypogastric plexus runs parallel to the blood vessels of the paracolpium (Fig. 9).

Step 9: Separation and division of the uterine branch from the inferior hypogastric plexus

If we trace the hypogastric nerve toward the posterior-lateral wall of the uterus, we can appreciate the inferior hypogastric plexus (Fig. 9) formed by the hypogastric nerve, the splanchnic nerve, the bladder branch, and the uterine branch from the inferior hypogastric plexus (cross-shaped). These nerves reside in the same connective tissue plane that we call the pelvic nerve plane. On the same level of the hypogastric nerve, the bladder branch from the inferior

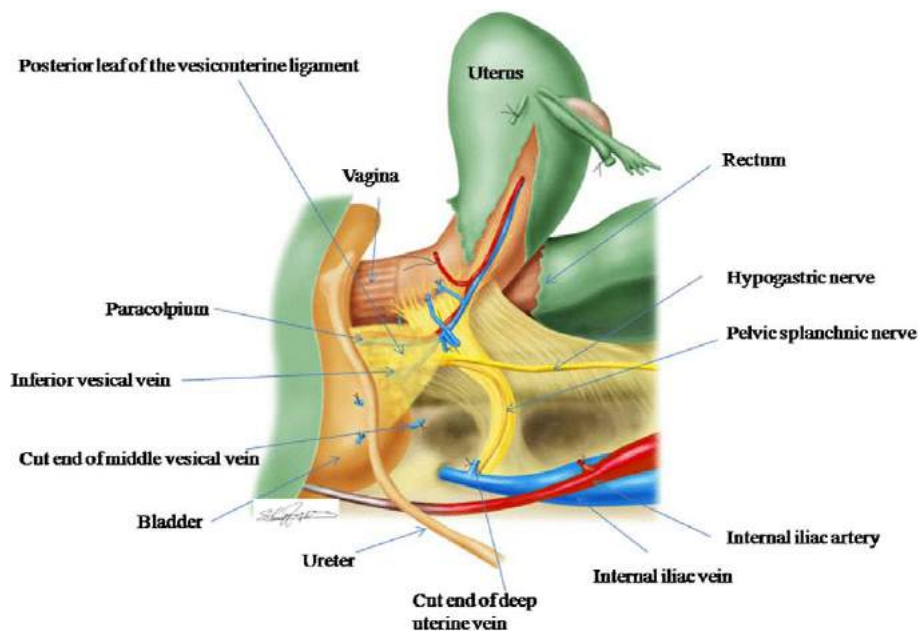


Fig. 8. Division of the middle vesical vein.

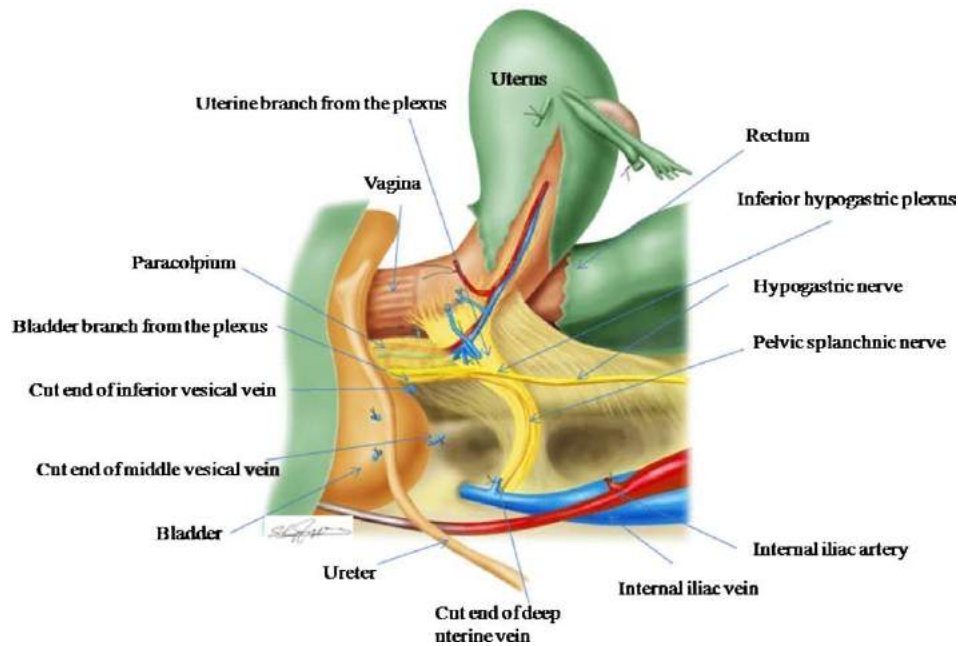


Fig. 9. Division of the inferior vesical vein reveals the bladder branch from the inferior hypogastric plexus.

hypogastric plexus can be separated from the blood vessels of the paracolpium. Pean's forceps is introduced (Fig. 10) at the v-shaped depression created between the bladder branch and the blood vessels of the paracolpium into the connective tissue between the pelvic nerve plane and the cervix/upper vagina slightly to the ventral side of the hypogastric nerve and slightly to the dorsal side of the cut end of the deep uterine vein. The uterine side of the pelvic nerve plane including the uterine branch from the inferior hypogastric plexus is clamped, divided, and ligated (Fig. 11). When the

uterine branch of the pelvic nerves is cut, the surgeon will experience a sensation similar to that of a stretched string breaking with a snap. After the division of the uterine branch, the hypogastric nerve, the pelvic splanchnic nerve and the bladder branch of the inferior hypogastric plexus forms the T-shaped nerve plane (Fig. 11).

Step 10: Division of the rectovaginal ligament

By pushing the rectum up, the rectovaginal ligament rises to the surface between the pelvic nerve plane and the rectum (Fig. 12). Only the rectovaginal ligament is divided

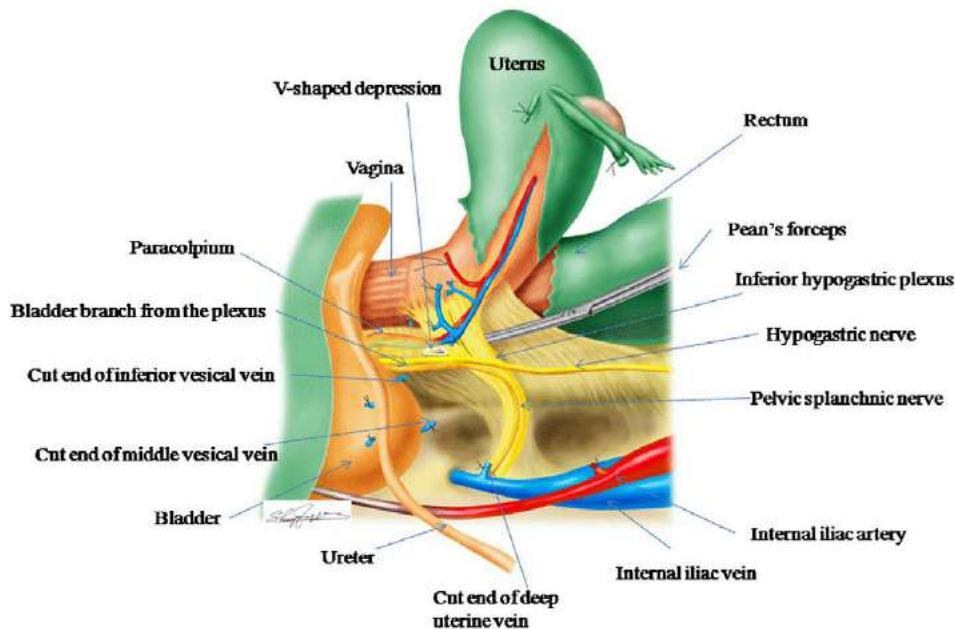


Fig. 10. Cross-shaped inferior hypogastric plexus and isolation of the uterine branch from the plexus.

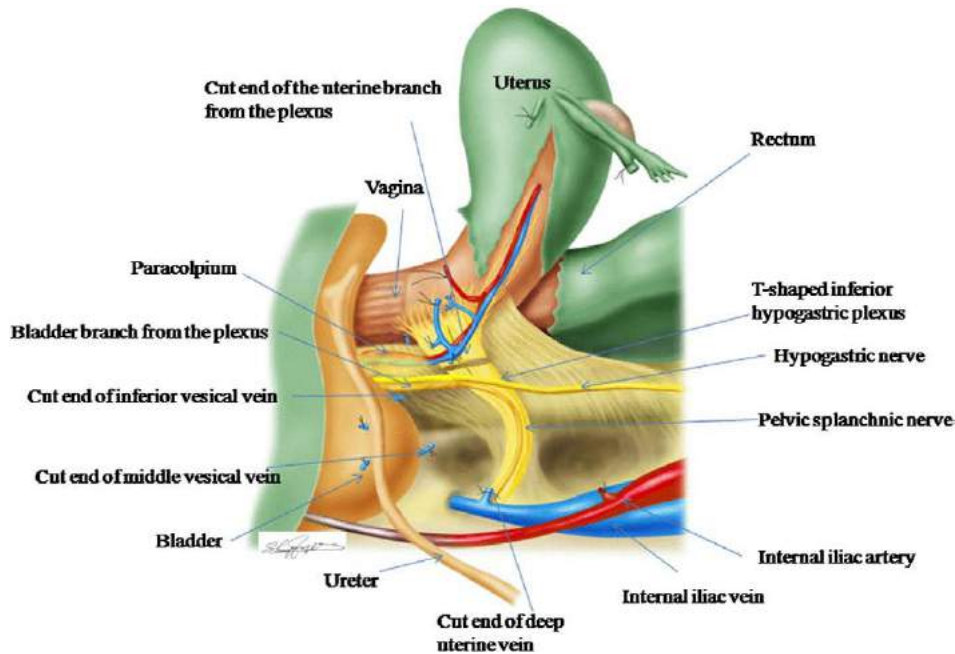


Fig. 11. Division of the uterine branch creates T-shaped nerve plane of the inferior hypogastric plexus.

using bipolar scissors toward the upper vagina, excluding the T-shaped nerve plane (Fig. 13).

Step 11: Separation and division of the paracolpium

If we divide the remaining rectovaginal ligament close to the upper vagina (Fig. 13), the bladder branch from the inferior hypogastric plexus forming the T-shaped nerve plane is gradually separated from the blood vessels of the paracolpium. The separation can extend caudally

to obtain vaginal length deemed appropriate by the level of cervical disease. At the designated level, the blood vessels of the paracolpium are clamped, cut, and ligated (Fig. 14). The T-shaped nerve plane formed by the hypogastric nerve, the pelvic splanchnic nerve, and the bladder branch of the inferior hypogastric nerve is completely preserved.

Step 12: Extirpation of the uterus

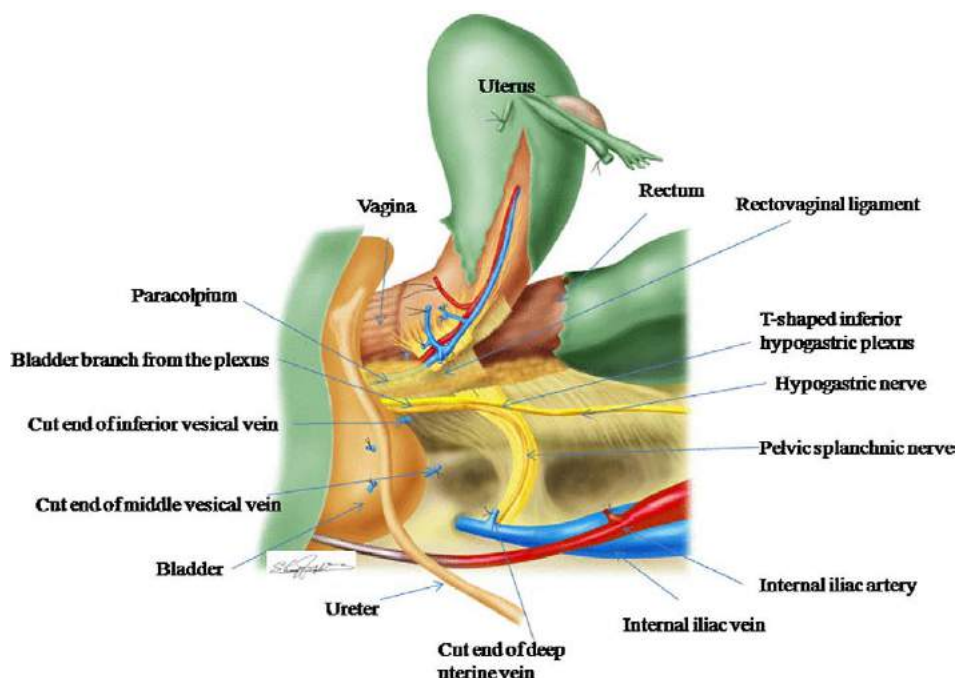


Fig. 12. Division of the rectovaginal ligament.

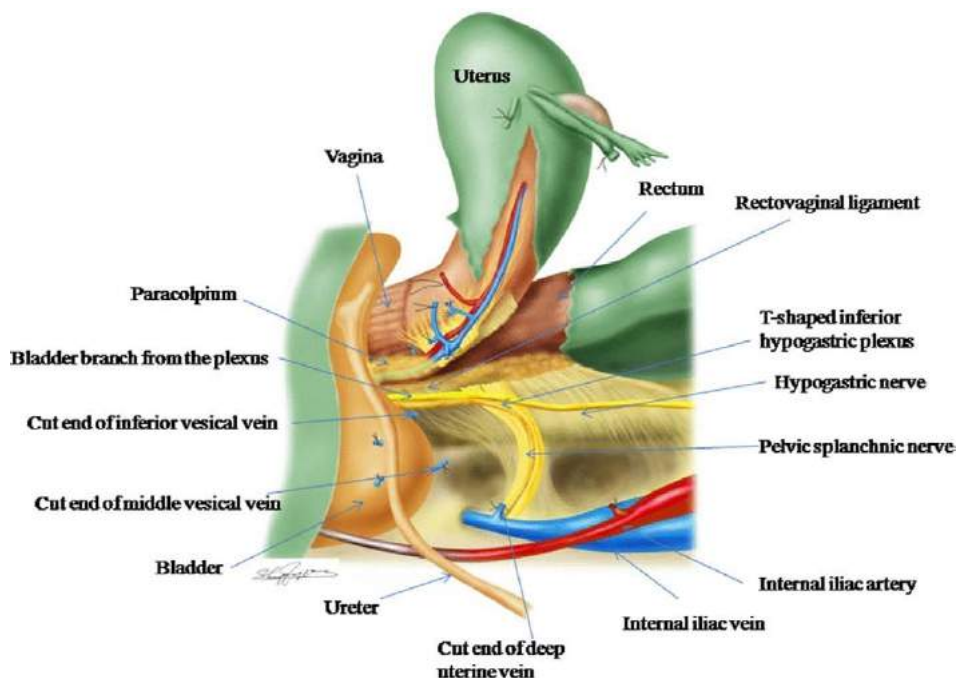


Fig. 13. Division of the rectovaginal ligament and isolation of the paracolpium.

By dividing the paracolpium, the uterus is only connected with the vagina. After the same procedure on the opposite side, the length of the vaginal cuff is confirmed. Then the uterus is amputated from the vagina (Fig. 15).

Conclusion

In order to accomplish the nerve-sparing radical hysterectomy, it is necessary to meticulously divide the posterior

leaf of the vesicouterine ligament. By the separation of the inferior vesical vein in the posterior leaf of the vesicouterine ligament, the bladder branch from the inferior hypogastric plexus can be identified and preserved. To better understand the nerve-sparing radical hysterectomy, I tried to illustrate the difference of the cutting line of the nerve-sparing radical hysterectomy to the original Okabayashi radical hysterectomy at the level of the upper vagina by cross section (Fig. 16).

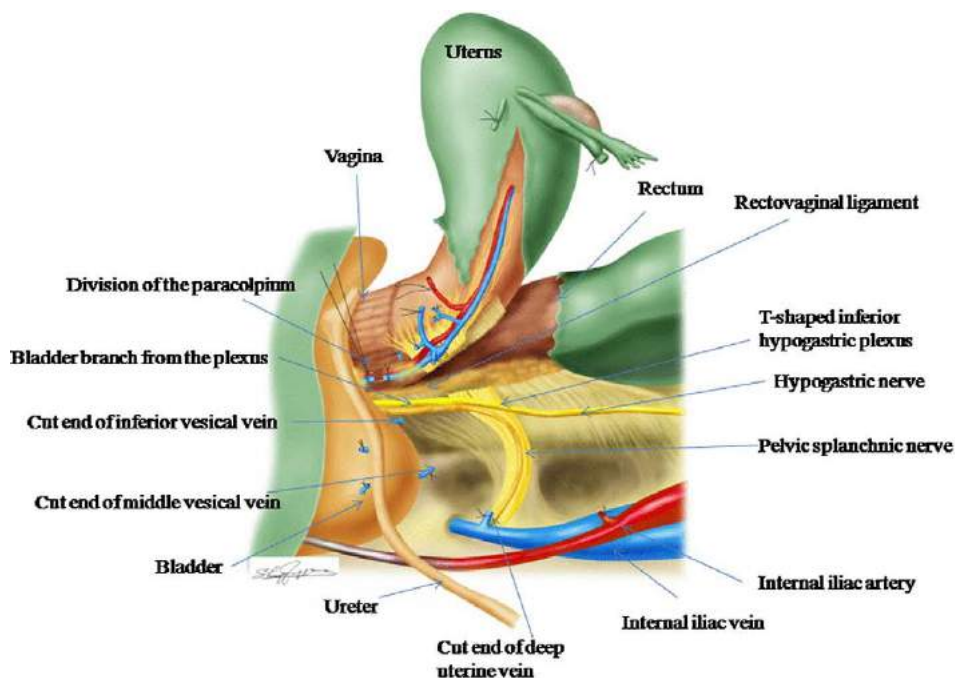


Fig. 14. Division of the paracolpium.

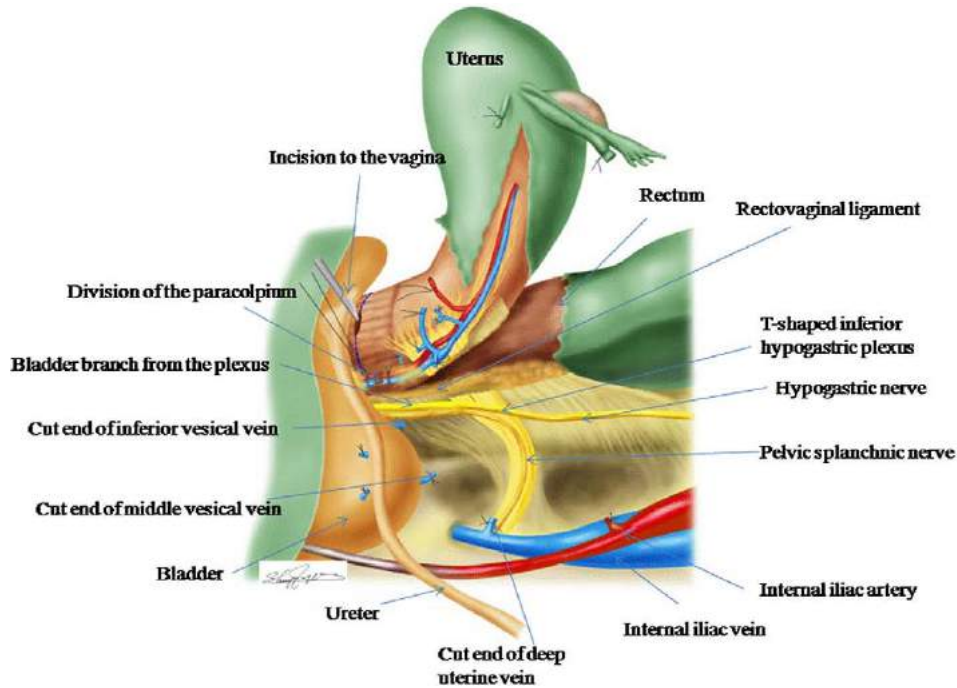


Fig. 15. Amputation of the vagina.

Conflict of interest statement

The author has no conflicts of interest to declare.

References

- [1] Wertheim E. Die erweiterte abdominale Operation bei Carcinoma colli Uteri (auf Grund von 500 Fallen). Berlin: Urban & Schwarzenberg; 1911.
- [2] Piver MS, Rutledge F, Smith JP. Five classes of extended hysterectomy for women with cervical cancer. *Obstet Gynecol* 1974;44:265–72.
- [3] Okabayashi H. Radical abdominal hysterectomy for cancer of the cervix uteri, modification of the Takayama operation. *Surg Gynecol Obstet* 1921;33:335–41.
- [4] Fujii S, Takakura K, Matsumura N, Higuchi T, Yura S, Mandai M, et al. Anatomic identification and functional outcomes of the nerve sparing Okabayashi radical hysterectomy. *Gynecol Oncol* 2007;107:4–13.
- [5] Fujii S, Takakura K, Matsumura N, Higuchi T, Yura S, Mandai M, et al. Precise anatomy of the vesico-uterine ligament for radical hysterectomy. *Gynecol Oncol* 2007;104:186–91.

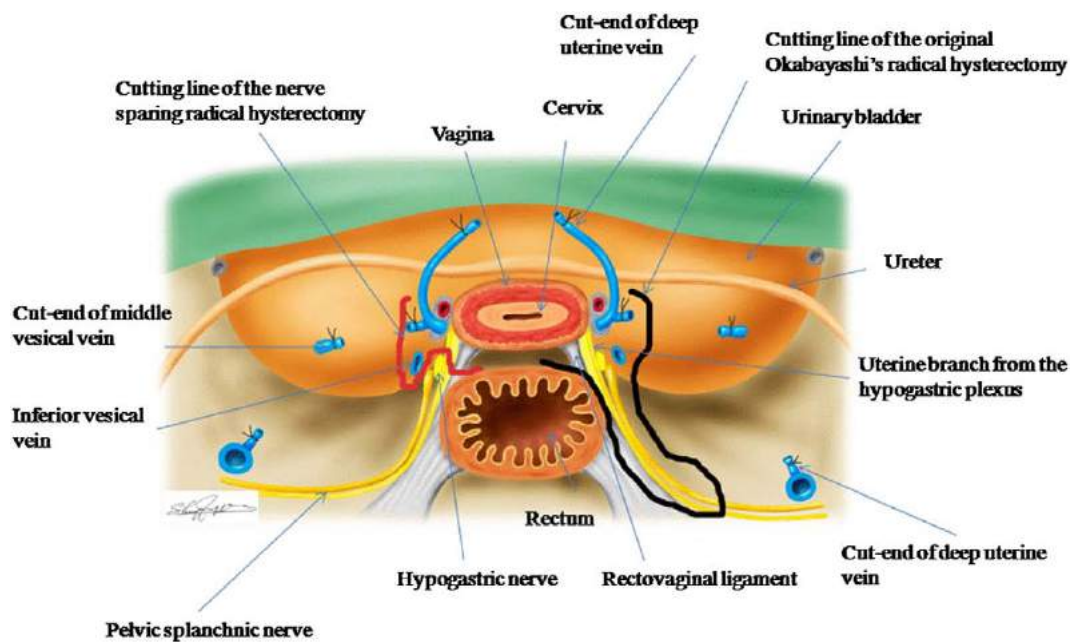


Fig. 16. Cutting line of the nerve-sparing radical hysterectomy vs. original Okabayashi radical hysterectomy.