



Contents lists available at ScienceDirect

Gynecologic Oncology

journal homepage: www.elsevier.com/locate/ygyno

The significance of comprehensive staging surgery in malignant ovarian germ cell tumors

Qian Liu^a, Xilai Ding^{a,*}, Jiaxin Yang^{a,*}, Dongyan Cao^a, Keng Shen^a, Jinghe Lang^a, Guonan Zhang^b, Xiaoyan Xin^c, Xing Xie^d, Yumei Wu^e

^a Department of Obstetrics and Gynecology, Peking Union Medical College Hospital, Peking Union Medical College, Chinese Academy of Medical Sciences, Beijing, China

^b Department of Obstetrics and Gynecology, Sichuan Province Tumor Hospital, Sichuan, China

^c Department of Obstetrics and Gynecology, Xijing Hospital, Shanxi, China

^d Obstetrics and Gynecology Hospital attached to Medical College of Zhejiang University, Zhejiang, China

^e Beijing Obstetrics and Gynecology Hospital attached to Capital University of Medical Sciences, Beijing, China

HIGHLIGHTS

- Compared with CSS group USO group had higher surgical security, satisfactory prognosis, considerable pregnancy and birth rate.
- It is safer and more effective for MOGCTs to perform ipsilateral adnexectomy + clinical intraoperative exploration and adjuvant chemotherapy.

ARTICLE INFO

Article history:

Received 18 April 2013

Accepted 15 August 2013

Available online xxx

Keywords:

Germ cell tumors

Complete staging surgery

ABSTRACT

Objective. To evaluate the clinical significance of fertility-preserving comprehensive staging surgery (CSS) in the treatment of malignant ovarian germ cell tumors (MOGCTs).

Methods. A total of 92 cases of MOGCTs were retrospectively reviewed.

Results. Forty-six patients (50%) received CSS, which includes ipsilateral adnexectomy + omentectomy + retroperitoneal lymphadenectomy (appendectomy and multiple biopsies as required). Forty-six patients (50%) received USO, which includes ipsilateral adnexectomy + clinical intraoperative evaluation (including retroperitoneal lymph nodes, great omentum, peritoneal, and contralateral ovary), biopsy of suspicious sites, and excision of all visible lesions. The mean operation time (177.0 vs. 114.8 min; $p < 0.0001$) and the mean intraoperative blood loss (499.1 ml vs. 112.9 ml; $p = 0.04$) were significantly higher in the CSS group compared to those in the USO group. The complication rate (17.4% vs 0%, $p = 0.003$), the relapse rate (10.9% vs 2.2%, $p = 0.102$) and the mortality rate (4.3% vs 2.2%, $p = 0.500$) were higher in the CSS group compared to those in the USO group. The difference in complication rate was statistically significant. The overall 5 year survival rates were 92% and 97% in the CSS and USO groups, respectively ($p = 0.575$). Tumor-free survival rates at 5 years were 87% and 97% in the CSS and USO groups, respectively ($p = 0.115$).

Conclusions. The benefit of fertility-preserving CSS to MOGCT patients was not greater than that of USO. It is safer and more effective to perform ipsilateral adnexectomy + clinical intraoperative exploration surgery (including retroperitoneal lymph nodes, great omentum, peritoneal, and contralateral ovary), biopsy of suspicious sites, excision of all visible lesions, and adjuvant chemotherapy.

© 2013 Elsevier Inc. All rights reserved.

Introduction

Malignant ovarian germ cell tumors (MOGCTs) mostly occur in young women. In women younger than 20 years old, 58% of ovarian tumors are germ cell tumors (GCTs), 1/3 of which are malignant [1]. These tumors grow rapidly, are highly malignant, and result in high mortality.

Except for dysgerminoma, MOGCTs are unilateral in approximately 95% of cases. Disease recurrence is usually not in the pelvic cavity itself, and both uterine and contralateral adnexa are rarely involved [2,3]. The presence of bilateral lesions is not an independent prognostic factor [3].

In recent years, adjuvant chemotherapy with cisplatin + vincristine + bleomycin (PVB) or cisplatin + etoposide + bleomycin (PEB) has been used in clinical practice to successfully treat MOGCT. For this reason, fertility-preserving surgery becomes the first treatment option, with its application not being limited by tumor stage [4–8].

In the current study we report on a multi-center study comparing different types of fertility-preserving surgery in MOGCT treatment.

* Corresponding authors at: Department of Obstetrics and Gynecology, Peking Union Medical College Hospital, Shuai Fu Yuan 1#, Dong Dan, Dongcheng District, Beijing 100730 China. Fax: +86 10 65296247.

E-mail address: dingxilai00@163.com (X. Ding).

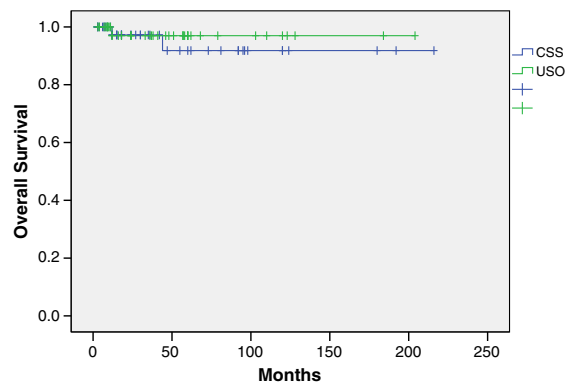


Fig. 1. Comparison of overall survival in CSS and USO groups. The survival rates at 5 years were 92% and 97% ($p < 0.05$) for CSS and USO groups, respectively.

The study evaluates treatment outcome, fertility, and complications to provide a basis for selection of appropriate surgical methods.

Materials and methods

This study included 92 treatment-naïve patients seen at 10 hospitals, including Peking Union Hospital and Sichuan Province Tumor Hospital, from September 1992 to November 2010. All patients were referred for treatment of histologically diagnosed MOGCTs.

Patient inclusion criteria were: ≤ 40 years old of age, desiring fertility, no other infertility factors present in the couple, desire to receive fertility-preserving surgery, and availability for follow-up.

Detailed records of clinical pathology, treatment, and follow-up were available for all eligible patients. According to the type of surgery received, the patients were divided into two groups, the comprehensive staging surgery (CSS) group and the ipsilateral salpingo-oophorectomy (USO) group. Patients in the CSS group received CSS, which included

ipsilateral adnexectomy + omentectomy + retroperitoneal lymphadenectomy (including appendectomy and multiple biopsies as required). Patients in the USO group received ipsilateral adnexectomy and clinical intraoperative evaluation (including retroperitoneal lymph nodes, great omentum, peritoneal, and contralateral ovary), biopsy of suspicious sites, and excision of all visible lesions. The differences in treatment outcome, fertility, and complications between the two groups were retrospectively analyzed.

SPSS 18.0 statistical software was used in all statistical analyses, and differences between the two groups were compared using the chi-squared test. Survival curves were estimated using Kaplan–Meier method. $p < 0.05$ was considered statistically significant.

Results

Patient information

Out of 92 cases, 46 patients (50%) were included in the CSS group and 46 patients were included in the USO group. Fig. 1 is the bar graph with age distribution among the two strategies. There were no statistically significant differences between the two groups in terms of patient age, size of the tumors, International Federation of Gynecology and Obstetrics staging (FIGO), pathology, regimen of chemotherapy, treatment rounds, and follow-up period (Table 1). PEB/PVB was the primary postoperative adjuvant chemotherapy. Treatment courses ranged from 1 to 9; 77 out of 92 patients (83.7%) received 1–6 courses of treatment, and 14 out of 92 (15.2%) patients received more than 7 courses of treatment.

Comparison of surgery relevant parameters in the two groups

The operation time was significantly longer ($p < 0.05$) and the intraoperative blood loss was significantly ($p < 0.05$) greater in the CSS group compared to those in the USO group. The complication rate, relapse rate, and mortality were all higher in the CSS group than those in the USO group; the difference in complication rate was statistically significant ($p < 0.05$) (Table 2).

Table 1
Comparison of patients' characteristics in CSS and USO groups.

	CSS N = 46	USO N = 46	Sum N = 92	P value [*]
Age (years)	20.1	22.2	21.0	0.255
Mean range	7–38	5–35	5–38	
Tumor size (cm)	13.1	12.2	12.7	0.471
Mean range	5–28	4–25	4–28	
Time of initiation of chemotherapy after surgery (day)	3.1	1.9	2.6	0.09
FIGO stage (%)	23 (50.0)	15 (32.6)	38 (41.3)	0.132
Stage I + stage II (%)	16 (34.8)	14 (30.4)	30 (32.6)	
Stage III + stage IV (%)	7 (15.2)	1 (2.2)	8 (8.7)	
Unidentified ^a	23 (50.0)	31 (67.4)	54 (58.7)	
Pathological types (%)				0.370
Immature teratoma	15 (32.6)	17 (37.0)	32 ^b (34.8)	
Endodermal sinus tumor	18 (39.1)	13 (28.3)	31 (33.7)	
Dysgerminoma	12 (26.1)	9 (19.6)	21 (22.8)	
Others ^c	1 (2.2)	7 (15.2)	8 (8.7)	
Chemotherapy (%)				0.247
PEB/PVB	46 (100)	42 (91.3)	88 (95.7)	
Others ^d	0 (0)	4 (8.7)	4 (4.3)	
Courses of treatment (mean)	5.4	4.9	5.1	0.058
Follow-up period (months)	51.2	48.8	50.0	0.819
Mean range	3–216	3–204	3–216	

^{*} Wilcoxon rank test or Chi-square test.

^a Unidentified: No staging.

^b Among the 32 cases immature teratoma, 10 cases (31.3%) were G1, 13 cases (40.6%) were G2, and 9 cases (28.1%) were G3.

^c 4 cases (4.3%) were mixed cell tumor, 3 cases (3.3%) were primary choriocarcinoma, and 1 case (1.1%) was ovarian follicular thyroid papillary carcinoma.

^d Among the 4 cases, 2 cases were EMA/CO (actinomycin D, methotrexate, etoposide, vincristine, cyclophosphamide), 1 case was VAC (Vincristine, adriamycin, cisplatin), and 1 case did not receive any chemotherapy.

Table 2

Comparison of surgery relevant parameters in the two groups.

	CSS N = 46	USO N = 46	Sum N = 92	P value*
Operation time	177.0	114.8	152.5	<0.001
Mean range	40–300	30–245	30–300	
Intraoperative blood loss	499.1	112.9	344.6	0.004
Mean range	50–3800	20–350	20–3800	
Complication rate (%)	8 (17.4) ^a	0 (0)	8 (8.7)	0.003
Relapse rate (%)	5 (10.9)	1 (2.2)	6 (6.5)	0.102
Mortality (%)	2 (4.3)	1 (2.2)	3 (3.3)	0.500

* Wilcoxon rank test or Chi-square test.

^a Among the 8 complications, 4 (4.3%) cases were intestinal obstruction, and 4 (4.3%) cases were lymphatic cyst.

Fertility outcome of patients

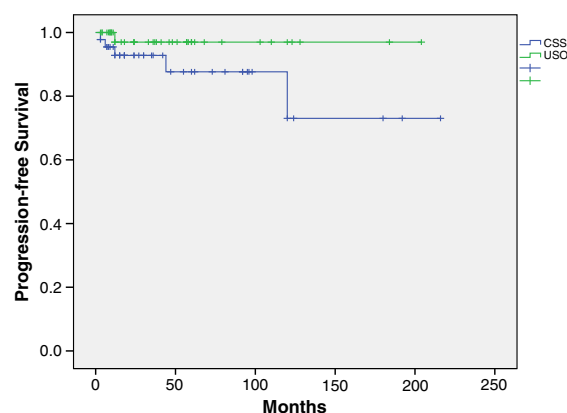
Out of the total 92 patients, 13 patients had no menarche; 2 patients (2.5%) suffered from amenorrhea after chemotherapy, and 1 patient failed to get pregnant, and the other had no fertility requirement then. 37 patients (40.2%) desired fertility, 17 patients (45.9%) got pregnant, and 15 patients (40.5%) got live births. The pregnancy rate and live birth rate of the CSS group and USO group were 47.4%, 42.1% and 44.4%, 38.9%, respectively. The differences in pregnancy rate and birth rate between the two groups were not statistically significant ($p > 0.05$).

Patient relapse and survival

The mean follow-up period for the 92 patients was 50.0 months. There were 3 deaths (Table 3). The three fatalities were among the very young, and the average age of the fatalities was twelve. The survival rates at 5 years in the CSS group and USO group were 92% and 97% ($p = 0.575$), respectively, and the tumor-free survival rates at 5 years were 87% and 97% ($p = 0.115$), respectively. The survival curves are shown in Figs. 2 and 3.

Discussion

Comprehensive staging surgery in the treatment of MOGCTs is based on the clinical practice management guidelines for women with ovarian epithelial tumors. However, in view of the characteristics of MOGCTs, fertility-preserving surgery is widely accepted. If the contralateral ovary and uterus have not been affected, it is sufficient to remove the ipsilateral adnexa, visible metastatic tumors in the pelvic cavity, great omentum, and retroperitoneal lymph nodes below the left renal vein, and to perform multiple biopsies in the peritoneal and pelvic cavity. In comparison, fertility-preserving CSS is more difficult and can only be performed by gynecologic oncologists due to the wider scope of the operation and the higher complication rate. In the current study, the complication rate, intraoperation blood loss, and mean operation time for the CSS group were all significantly higher compared to those for the USO group ($p < 0.05$). MOGCTs occur mostly in young women and young girls who wish to preserve fertility. Therefore, it is important to narrow the scope of operation and reduce operation trauma without

**Fig. 2.** Comparison of tumor-free survival in CSS and USO groups. The tumor-free survival rates at 5 years were 87% and 97% ($p > 0.05$) for CSS and USO groups, respectively.

compromising cure rate. Currently, the use of a surgical regimen that narrows the scope of the operation is controversial.

Adjuvant chemotherapy with PEB or PVB has made it possible to cure MOGCTs. The aim of the surgery is to remove tumors as cleanly as possible to maximize the effectiveness of chemotherapy. The high sensitivity of tumors to adjuvant chemotherapies, especially to those containing platinum and bleomycin, effectively supports the use of a surgical regimen with a narrowed scope of operation. In the study reported by Kang et al. [9], 77 patients (61%) received omentectomy, 23 patients had no visible lesions, and only 1 patient (1/23) had histologically positive omentum. Approximately half of the patients received comprehensive exploration of retroperitoneal lymph nodes. No abnormalities were found during the explorations and no lymph nodes were affected according to the pathological examination. Among the patients with enlarged and immobilized lymph nodes detected during the exploration, only 41% is confirmed to have lymph node metastasis. This study raises the question: Should greater omentum and retroperitoneal lymph nodes without visible lesions continue to be preserved?

It was reported that retroperitoneal lymph node metastasis was not associated with recurrence of the disease and long-term survival [10,11]. In early stage MOGCT patients, Mahdi et al. [12] found that neither retroperitoneal lymph node excision nor lymph node metastases were independent prognostic factors for lesions confined to the ovaries. In addition, chemotherapy was effective in treatment of retroperitoneal lymph node metastasis. It was shown in the literature that 9% of stage I and 24% stage II MOGCT patients were evaluated as stage III because of lymph node involvement. Therefore, conducting staging surgery in early stage patients could only define the stages, but could not significantly improve the prognosis.

For patients with stage III and IV disease, resection of the omentum, appendix, and retroperitoneal lymph nodes could not further determine staging. Therefore, it is pertinent to ask: Could CSS improve the prognosis of these patients? Jin Ying et al. [10] found that compared to patients who did not receive comprehensive surgery, CSS, including excision of omentum and retroperitoneal lymph nodes performed in patients at or above stage III, reduced relapse and prolonged survival, although

Table 3

Patient information in death cases.

	Age (years)	Pathological type	Stage	Surgery	Chemotherapy	Relapse interval (months)	Relapse site	Cause of death
Case 1	12	endodermal sinus tumor	IV	CSS	PEB * 6	12	Pelvic cavity Liver	Multiple recurrence
Case 2	10	endodermal sinus tumor	unknown	CSS	PEB * 8	43	liver	Multiple recurrence
Case 3	14	immature teratoma	unknown	USO	PEB * 5	12	Multiple recurrence	Multiple recurrence Lung infection

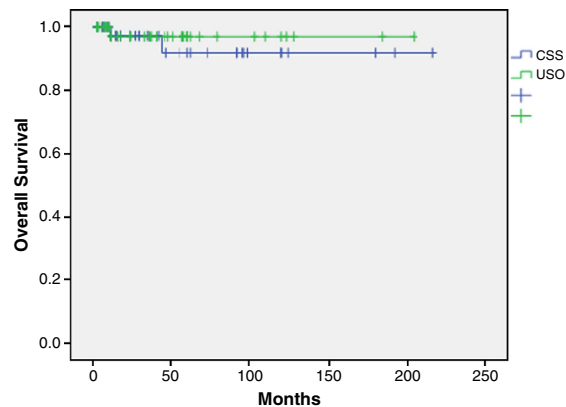


Fig. 3. Comparison of tumor-free survival of the two groups.

the improvements were not statistically significant ($p = 0.931$). In the current study, no differences were found in the age of patients, pathological types, FIGO staging, regimen of postoperative chemotherapy, and mean courses of treatment between the two groups. The two groups were therefore comparable, and these factors could be excluded as confounding factors for differences in prognosis. The results of this study showed that there were no statistically significant differences found between the two groups in terms of relapse rate, mortality, survival rate at 5 years, and tumor-free survival rate at 5 years. These results suggest that CSS does not improve patient prognosis, but has a higher complication rate and more operative blood loss. The survival rate at 5 years and tumor-free survival rate at 5 years were both as high as 97% in the surgery regimen of ipsilateral adnexectomy + clinical intraoperative exploration. This regimen was safe and reliable. Therefore, with the effective protection of adjuvant chemotherapy, it is safe to preserve omentum and retroperitoneal lymph nodes that are found to be lesion-free during exploration.

It was previously reported that the pregnancy rate in fertility-preserving surgery and standard adjuvant chemotherapy was 13.3%–42.3% [9,13,14]. In the current study, the number of patients desiring fertility at last follow-up was 37 cases, and the pregnancy rate (45.9%) and birth rate (40.5%) were higher than those reported in the literature. In our study, there were no statistically significant differences between the two surgery regimens with regards to pregnancy rate and birth rate.

In summary, this large sample size multicenter study evaluated fertility-preserving surgeries in ovarian germ cell tumors. Fertility-preserving CSS did not bring additional benefit to patients with MOGCTs

compared to ipsilateral adnexectomy + clinical intraoperative exploration. It is safe to perform ipsilateral adnexectomy, clinical intraoperative exploration (including retroperitoneal lymph nodes, omentum, peritoneal, contralateral ovarian), biopsy of suspicious sites, resection of visible lesions, and postoperative standard adjuvant chemotherapy in MOGCT patients. Although the follow-up time was relatively short, this study provides an important basis for selection of treatment regimen.

Conflict of interest statement

The authors declare that there are no conflicts of interest.

Acknowledgments

This work was supported by grant no. 2008BAI57B02 from the National Technology Supporting Program.

References

- [1] Norris HJ, Jensen RD. Relative frequency of ovarian neoplasms in children and adolescents. *Cancer* 1972;30(3):713–9.
- [2] Roychoudhuri R, Putcha V, Moller H. Cancer and laterality: a study of the five major paired organs (UK). *Cancer Causes Control* 2006;17(5):655–62.
- [3] Mahdi H, Kumar S, Seward S, Semaan A, Batchu R, Lockhart D, et al. Prognostic impact of laterality in malignant ovarian germ cell tumors. *Int J Gynecol Cancer* 2011;21(2):257–62.
- [4] Abdel-Hady E, Abdel-Hady HR, Gamal A. Fertility sparing surgery for ovarian tumors in children and young adults. *Arch Gynecol Obstet* 2012;285(2):469–71.
- [5] Yoo SC, Kim WY, Yoon JH, Chang SJ, Chang KH, Ryu HS. Young girls with malignant ovarian germ cell tumors can undergo normal menarche and menstruation after fertility-preserving surgery and adjuvant chemotherapy. *Acta Obstet Gynecol Scand* 2010;89(1):126–30.
- [6] Tangir J, Zelterman D, Ma W, Schwartz PE. Reproductive function after conservative surgery and chemotherapy for malignant germ cell tumors of the ovary. *Obstet Gynecol* 2003;101(2):251–7.
- [7] Kesic V. Fertility after the treatment of gynecologic tumors. *Recent Results Cancer Res* 2008;178:79–95.
- [8] Gershenson DM. Fertility-sparing surgery for malignancies in women. *J Natl Cancer Inst Monogr* 2005;34:43–7.
- [9] Kang H, Kim TJ, Kim WY, Choi CH, Lee JW, Kim BG, et al. Outcome and reproductive function after cumulative high-dose combination chemotherapy with bleomycin, etoposide and cisplatin (BEP) for patients with ovarian endodermal sinus tumor. *Gynecol Oncol* 2008;111(1):106–10.
- [10] Jin Y, Pan LY, Huang HF, Shen K, Wu M, Yang JX, et al. Lymphadenectomy in the treatment of malignant ovarian germ cell tumor. *Zhongguo Yi Xue Ke Xue Yuan Xue Bao* 2005;27(6):743–8.
- [11] Kumar S, Shah JP, Bryant CS, Imudia AN, Cote ML, Fehmi RA, et al. The prevalence and prognostic impact of lymph node metastasis in malignant germ cell tumors of the ovary. *Gynecol Oncol* 2008;110(2):125–32.
- [12] Mahdi H, Swensen RE, Hanna R, Kumar S, Ali-Fehmi R, Semaan A, et al. Prognostic impact of lymphadenectomy in clinically early stage malignant germ cell tumour of the ovary. *Br J Cancer* 2011;105(4):493–7.
- [13] Ayhan A, Taskiran C, Bozdag G, Altinbas S, Altinbas A, Yuce K. Endodermal sinus tumor of the ovary: the Hacettepe University experience. *Eur J Obstet Gynecol Reprod Biol* 2005;123(2):230–4.
- [14] Mitchell PL, Al-Nasiri N, A'Hern R, Fisher C, Horwich A, Pinkerton CR, et al. Treatment of nondysgerminomatous ovarian germ cell tumors: an analysis of 69 cases. *Cancer* 1999;85(10):2232–44.